

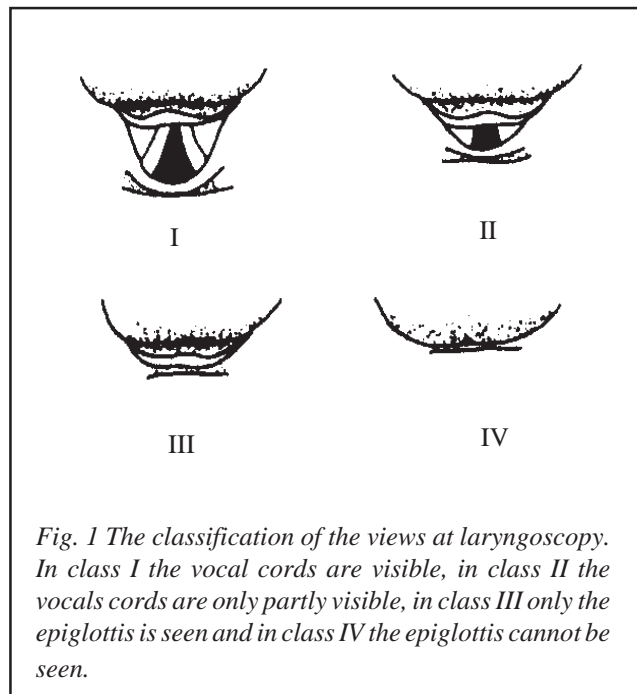
PREDICTION AND MANAGEMENT OF DIFFICULT TRACHEAL INTUBATION

*Dr I H Wilson, Department of Anaesthesia,
Royal Devon and Exeter Hospital, Exeter,
EX2 5DW*

*Dr Andreas Kopf, Department of Anaesthesia,
Benjamin Franklin Medical Centre, Free
University of Berlin, Hindenburgdamm 30
12200 Berlin-Lichterfelde, Germany*

INTRODUCTION

During routine anaesthesia the incidence of difficult tracheal intubation has been estimated at 3-18%. Difficulties in intubation have been associated with serious complications, particularly when failed intubation has occurred. Occasionally in a patient with a difficult airway, the anaesthetist is faced with the situation where mask ventilation proves difficult or impossible. This is one of the most critical emergencies that may be faced in the practice of anaesthesia. If the anaesthetist can predict which patients are likely to prove difficult to intubate, he may reduce the risks of anaesthesia considerably. This paper reviews clinical techniques used for predicting difficulties in intubation and suggests different approaches to manage these patients.



There have been various attempts at defining what is meant by a difficult intubation. Repeated attempts at intubation, the use of a bougie or other intubation aid have been used in some papers, but perhaps the most widely used classification is by Cormack and Lehane [1] which describes the best view of the larynx seen at laryngoscopy (figure 1). This should be recorded in the patient's notes whenever an

anaesthetic is administered so there is a record for future use.

PREDICTING DIFFICULT INTUBATION

Tracheal intubation is best achieved in the classic “sniffing the morning air” position in which the neck is flexed and there is extension at the cranio-cervical (atlanto-axial) junction. This aligns the structures of the upper airway in the optimum position for laryngoscopy and permits the best view of the larynx when using a curved blade laryngoscope. Abnormalities of the bony structures and the soft tissues of the upper airway will result in difficult intubation.

History and examination

Pregnant patients, those suffering from facial/maxillary trauma, those with small mandibles or intra-oral pathology such as infections or tumours are all more likely to present difficulties during intubation.

Patients who suffer with rheumatoid disease of the neck or degenerative spinal diseases often have reduced neck mobility making intubation harder. In addition spinal cord injury may result from excessive neck movements during intubation attempts. Poor teeth and the inability to open the mouth are obvious other factors as are obesity, and inexperience on the part of the anaesthetist.

Specific Screening Tests to Predict Difficult Intubation.

A history of successful or unsuccessful intubation during previous anaesthesia is obviously significant.

There are a number of specific clinical assessments that have been developed to try to identify patients who will prove difficult to intubate.

Mallampati suggested a simple screening test which is widely used today in the modified form produced by Samsoon and Young [2]. The patient sits in front of the anaesthetist and opens the mouth wide. The patient is assigned a grade according to the best view obtained (figure 2). Clinically, Grade 1 usually predicts an easy intubation and Grade 3 or 4 suggests a significant chance that the patient will prove difficult to intubate. The results from this test are influenced by the ability to open the mouth, the size and mobility of the tongue and other intra-oral structures and movement at the craniocervical junction.

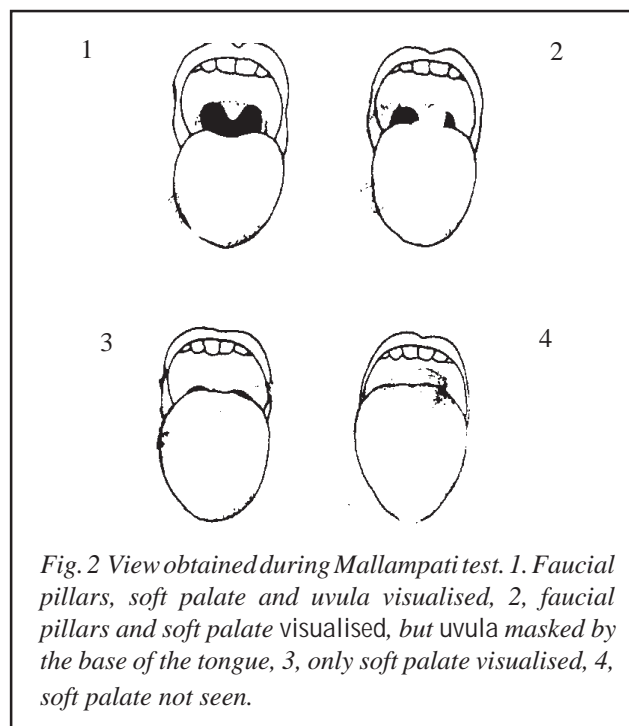


Fig. 2 View obtained during Mallampati test. 1. Faucial pillars, soft palate and uvula visualised, 2, faucial pillars and soft palate visualised, but uvula masked by the base of the tongue, 3, only soft palate visualised, 4, soft palate not seen.

Thyromental distance This is a measurement taken from the thyroid notch to the tip of the jaw with the head extended. The normal distance is 6.5cm or greater and is dependant on a number of anatomical factors including the position of the larynx. If the distance is greater than 6.5cm, conventional intubation is usually possible. If it is less than 6cm intubation may be impossible [3].

By combining the modified Mallampati and thyromental distance, Frerk showed that patients who fulfilled the criteria of Grade 3 or 4 Mallampati who also had a thyromental distance of less than 7cm were likely to present difficulty with intubation [4]. Frerk suggests that using this combined approach should predict the majority of difficult intubations. A 7cm marker can be used (eg a cut off pencil or an appropriate number of examiners fingers) to determine whether the thyromental distance is greater than 7cm.

Sternomental distance is measured from the sternum to the tip of the mandible with the head extended and is influenced by a number of factors including neck extension. It has also been noted to be a useful screening test for pre-operative prediction of difficult intubation. A sternomental distance of 12.5cm or less predicted difficult intubation [5].

Extension at the atlanto-axial joint should be assessed by asking the patient to flex their neck by putting their head forward and down. The neck is then held in this position and the patient attempts to

raise their face up testing for extension of the atlanto-axial joint. Laryngoscopy is optimally performed with the neck flexed and extension at the atlanto-axial joint. Reduction of movement at this joint is associated with difficulty.

Protrusion of the mandible is an indication of the mobility of the mandible. If the patient is able to protrude the lower teeth beyond the upper incisors intubation is usually straightforward [6]. If the patient cannot get the upper and lower incisors into alignment intubation is likely to be difficult.

Wilson et al [7] studied a combination of these factors in a surgical population assigning scores based on the degree of limitation of mouth opening, reduced neck extension, protuberant teeth and inability to protrude the lower jaw. Although their method can predict many difficult intubations, it also produces a high incidence of false positives (someone who is assessed as a likely difficult intubation, but who proves easy to intubate when anaesthetised) which limits its usefulness.

X ray studies Various studies have been used to try to predict difficult intubation by assessing the anatomy of the mandible on X ray. These have shown that the depth of the mandible may be important, but they are not commonly used as a screening test.

Preoperative assessment A combination of the above tests is better than using only one. The modified Mallampati, thyromental distance, ability to protrude the mandible and craniocervical movement are probably the most reliable.

Most patients without indicators of difficult intubation will prove easy to intubate under anaesthesia although occasional difficulties will occur. The majority of difficult intubations will be predicted by clinical assessment, but the tests will wrongly predict difficult intubation in some patients who will subsequently prove straightforward.

PREPARING FOR INTUBATION

Anaesthetists should be ready to deal with difficulties in intubation at any time. The correct equipment must be immediately available. This will include:

- laryngoscopes with a selection of blades
- a variety of endotracheal tubes
- introducers for endotracheal tubes (stylets or better, flexible bougies)
- oral and nasal airways
- a cricothyroid puncture kit (a 14 gauge cannula and jet insufflation with high pressure oxygen is the simplest and cheapest kit (see Update No 1996;6:4-5).
- reliable suction equipment
- a trained assistant
- laryngeal mask airways, sizes 3 & 4

The safety of laryngoscopy can be increased by preoxygenating the patient prior to induction and attempts at intubation. The anaesthetist should ensure that the patient is in the optimal position for intubation and must be able to oxygenate the patient at all times.

After intubation correct placement of the tube should be confirmed by:

- a stethoscope listening over both lung fields in the axillae
- observing the tube pass through the cords
- successful inflation of the chest on manual ventilation

Additional tests include the use of the oesophageal detector device (see Update No 1997;7:27-30) and a capnograph (if available).

Special techniques for intubation

When it is anticipated that a particular patient will present difficulties in intubation there are a number of options that need consideration. Regional anaesthesia is preferable to general anaesthesia whenever possible. However, in patients who require general anaesthesia with intubation, an awake intubation technique may be considered. This allows the patient to maintain their own airway and is the safest option.

Awake intubation under local anaesthesia

The aim with this technique is to anaesthetise the upper airway using local anaesthetic to allow tracheal intubation by a variety of techniques. This avoids the need for general anaesthesia and muscle relaxants to facilitate intubation. Either nasal or oral intubation may be performed, although the nasal route, despite the risk of haemorrhage, is often easier. The oral route is more stimulating and may be more difficult. The technique requires a co-

operative patient, and some experience on the part of the anaesthetist.

This technique may be performed using either a fibreoptic flexible bronchoscope or other fibroscope or using direct laryngoscopy. The patient is carefully prepared with a full explanation of why they are due to have awake intubation. Atropine 500mcg or glycopyrrolate 200mcg should be given intramuscularly half an hour before intubation to dry the mucous membranes, improving the action of the local anaesthetic and visibility. Oxygen at a rate of 2 - 3 litres/minute should be administered through a nasal catheter during the procedure (a suction catheter may be adapted for this purpose). The patient may be sedated gently during the procedure using small doses (2mg) of diazepam or other intravenous sedation. Small doses of opioid may also be helpful.

There are a variety of methods of producing local anaesthesia. Take care with the total dose of local anaesthetic used. A maximum of 4mg/kg lignocaine is usually recommended. Methods of producing anaesthesia include:

1. "Spray as you go" Lignocaine 2 - 4% is sprayed on to the mucosa of the upper airway as it is exposed during the intubation process. This can be done via a special dispenser, or using repeated small boluses from a syringe with a cannula (not a needle) firmly attached. Some anaesthetists give an injection of 2mls of 2% lignocaine through the cricothyroid membrane. This anaesthetises the trachea and the under-surface of the vocal cords.
2. If nasal intubation is planned, cocaine (avoid in patients with ischaemic heart disease) is the preferred anaesthetic for the mucosa of the nose as it is an active vasoconstrictor and reduces the incidence of nasal haemorrhage. It is placed in the nose as a paste using cotton wool buds.
3. Nebulised lignocaine (4mls of 4%) is used by some anaesthetists and claimed to be a useful technique. However it usually requires topical supplementation and is not as good for nasal intubation.

After successful anaesthesia to the airway has been achieved, the patient may be intubated in a number of ways.

Oral intubation. Patients who are well prepared with good anaesthesia may often be intubated using

a standard laryngoscope, but it is very stimulating unless preparation is excellent. If the laryngeal structures are easily seen during awake laryngoscopy general anaesthesia may be induced and the patient intubated conventionally. However patients who are difficult intubations will usually require a different technique. Awake fibreoptic intubation through the mouth is more difficult than through the nose due to the angulation involved in passing over the back of the tongue and round the epiglottis. In addition the patient may bite down on the endoscope unless a bite block is used.

Nasal intubation is the best method of awake intubation using a fibreoptic bronchoscope or other intubating fibroscope via the nose. The instrument is passed thorough the nose and into the trachea with an endotracheal tube mounted over it. After the trachea is entered the endotracheal tube is slid down over the scope into position. This equipment requires expertise and training and is not available in many parts of the world and will not be further considered in this article. However it should be remembered that there a variety of thin flexible fibreoptic scopes may be employed for awake intubation, including cystoscopes.

Some anaesthetists can perform a blind nasal intubation technique where a nasal endotracheal tube is gently passed through the nose towards the larynx. Breath sounds will be heard and the tube is guided in the direction of the loudest breath sounds by moving the patient's head until the larynx is entered. This technique requires a great deal of skill and expertise and is not feasible if the head and neck cannot be moved.

Retrograde intubation is a technique first described in Nigeria [8] for intubation of patients with cancrum oris. A wire or epidural catheter is passed through the cricothyroid membrane in a cephalad direction (towards the head) until it comes out of the nose or mouth. (In some patients it is necessary to grasp the catheter in the mouth using a pair of Magills forceps). At this point the patient has a wire running from within the trachea to the upper airway. An endotracheal tube is then inserted over this wire into the trachea from either the nasal or oral route. Ensure oxygenation is maintained throughout.

The bevel of the endotracheal tube should be posterior to make its passage into the larynx as

smooth as possible (figure 3). The tube may get obstructed at the level of the epiglottis or the vocal cords. There are a number of techniques to overcome this. The transtracheal wire may be used to guide a fiberoptic bronchoscope into the trachea and then the endotracheal tube placed over the scope. A larger hollow catheter may be placed over the wire into the trachea and the tube passed over the catheter. A disposable ureteric dilator which is hollow and has a tapered end is ideal for this. During the technique, if a nasal intubation is required but the wire comes out of the mouth, place another catheter through the nose, pull it out through the mouth, tie it to the wire, and then pull the wire up through the nose.

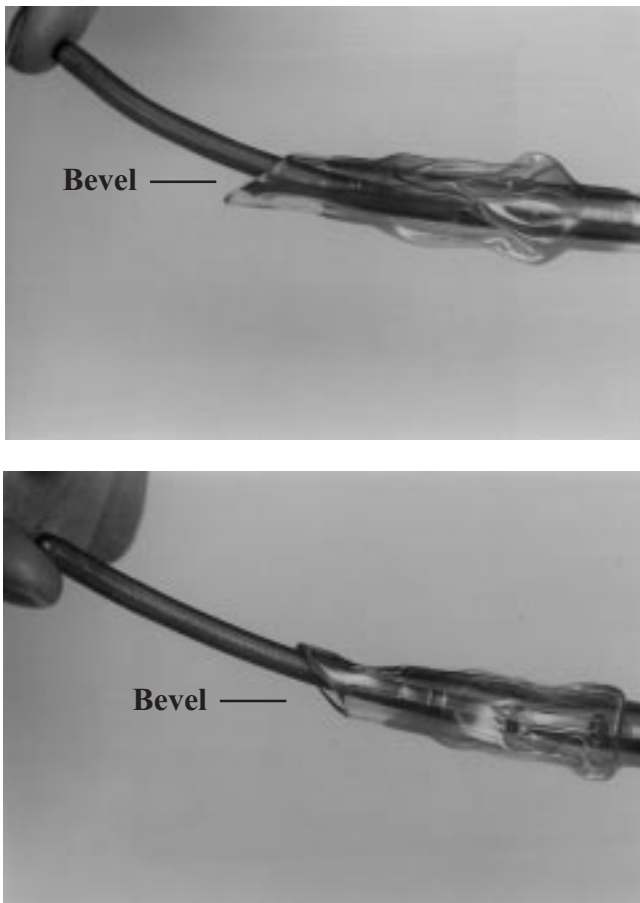


Figure 3. Bevel may stick on larynx if anterior
3b. Posterior bevel makes intubation easier

Retrograde intubation has recently been used successfully for traumatised airways when conventional techniques had failed [9], and there is a recent report suggesting that the membrane between the cricoid and first tracheal ring [10] can also be used.

Awake tracheostomy performed under local anaesthesia is the best solution when a patient is an impossible intubation, and regional anaesthesia is not a practical option. This is a straightforward technique, except in children, when sedation with ketamine has been used to facilitate this approach.

The Laryngeal Mask Airway (LMA - figure 4) is a common device in anaesthesia and can often provide a good airway in patients in whom intubation is difficult. Following insertion the anaesthetist may use it to maintain the airway during anaesthesia, or may use it as a route to allow tracheal intubation. A gum elastic bougie inserted down the laryngeal mask will often enter the trachea. A size 6 nasal tube may then be inserted through the mask, over the bougie, and the mask withdrawn if the tube enters the trachea. Unfortunately, on some occasions, the endotracheal tube is blocked by the fenestrations at the end of the laryngeal mask. The technique is best performed in conjunction with a fiberoptic bronchoscope.



Fig 4 The laryngeal mask airway

After insertion through the mask, the larynx may be identified and a bougie observed to pass through the chords. The scope and LMA are then withdrawn and an endotracheal tube passed in the normal fashion. Alternatively the scope may be introduced into the trachea and a size 6.0 tube inserted before the LMA is withdrawn. A special intubating LMA has been produced to facilitate this manoeuvre (Intavent Medical UK).

The McCoy laryngoscope (figure 5) is designed with a movable tip which allows the epiglottis to be lifted and intubation often made easier [11]. It is manufactured by Penlon UK Ltd.



Fig 5 The McCoy Laryngoscope

A **light wand** is a long flexible device which has a bright light at the end and can be directed into the trachea with an endotracheal tube mounted over it [12]. When it enters the trachea the light can be seen shining through the skin. A darkened room is required, and the technique is more difficult in obese patients.

The Combi-tube (figure 6) is a tube which may be inserted blindly and used to ventilate the patient in an emergency [13]. It is designed in such a way that the tube can be used for ventilation whether it enters the oesophagus or the trachea. On insertion the tube normally enters the oesophagus, the large balloon is inflated and the patient is ventilated via the holes in the pharynx. If the tube is in the trachea then ventilation is carried out via the tube after the cuff has been blown up.

Oral gastroscopes can be used in the absence of a bronchoscope. The scope is used to find the larynx and direct a stylet into the trachea followed by an endotracheal tube. Alternatively a wire may be passed through the scope into the larynx and a tube passed over it.

Deep inhalational induction of anaesthesia using oxygen with halothane or ether is a technique that has been widely used for patients anticipated to be difficult intubations. If airway obstruction develops, anaesthesia may be turned off and the patient woken up. During induction, when the patient is deeply anaesthetised direct laryngoscopy is performed. If the larynx is visible the patient may be intubated directly or be given a muscle relaxant, and the patient intubated. If the larynx proves difficult to visualise, but the airway is easy to manage and face mask ventilation is straightforward, then a dose of

muscle relaxant (preferably suxamethonium) can be safely given. Intubation may then be attempted in the normal way; if it is unsuccessful, ventilation is continued using the face mask. If the airway becomes obstructed and cannot be cleared the patient is best woken up. If aspiration is a potential problem the induction is best carried out in the head down, left lateral position.

This method is the technique of choice to secure the airway in children with acute upper airway obstruction, particularly those with croup or epiglottitis.

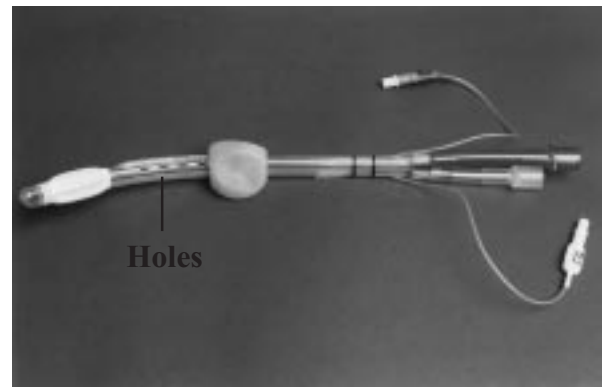


Fig 6 The Combi-tube

PLANNING ANAESTHESIA

When a difficult intubation is anticipated good planning is vital if anaesthesia is to be carried out safely. If general anaesthesia is essential and regional anaesthesia is not an option, the anaesthetist must decide whether the patient can be safely anaesthetised before an attempt is made at intubation. If the airway is likely to prove a problem then awake intubation is the best option before general anaesthesia is induced. **During general anaesthesia patients must never be given muscle relaxants unless the anaesthetist can be certain of being able to ventilate them.**

When the anaesthetist faces unexpected difficulty in intubation the priority is to ensure adequate mask ventilation and oxygenation of the patient. Multiple attempts at endotracheal intubation may result in bleeding and oedema of the upper airway making the task even more difficult. Often it is better to accept failure after a few attempts and move on to a pre-planned failed intubation sequence [14].

Failed intubation If intubation proves impossible the anaesthetist should consider whether to allow the patient to wake up and carry on surgery with regional anaesthesia, or whether to abandon the

surgery altogether. In situations where surgery is of an urgent nature it may be prudent to carry on the general anaesthetic under face mask anaesthesia if the airway is easy to maintain. If the airway is impossible to maintain and the patient is becoming hypoxic, an emergency cricothyroidotomy is required. If time allows an emergency tracheostomy can be considered.

Failure of face mask ventilation occurs when the patient has been anaesthetised and usually paralysed and face mask ventilation proves impossible. The priority is to ensure oxygenation by a number of emergency airway measures. The anaesthetist should attempt manoeuvres including chin lift, insertion of an oral and/or nasopharyngeal airway, and a jaw thrust procedure with both hands. If these techniques do not produce effective ventilation then an LMA should be inserted. (If an LMA is not available a Combi tube is another possibility). If there is still complete failure of ventilation then a cricothyroidotomy should be performed to deliver oxygen to the patient. Use a large intravenous cannula linked up to a high pressure oxygen system (as described in Update No. 6). There are commercially available devices for this purpose (Cook Critical Care Products). The cricothyroidotomy should be converted to an emergency tracheostomy as soon as possible (10 - 15 minutes maximum) or the patient allowed to wake up and regain their own airway.

Extubation of a patient who has been difficult to intubate should be performed with great care. There is a possibility that the patient may need re-intubation if there is a problem with extubation, and this may prove difficult or impossible. The patient should always be wide awake, co-operative and able to maintain their airway and ventilation before extubation is considered. If there are any doubts about the airway, the safest way to perform extubation is to insert a bougie or guide wire through the endotracheal tube and extubate the patient over this. The endotracheal tube may then be re-introduced over the bougie if the patient requires re-intubation. Some bougies are specially made for this (the Cook Critical Care endotracheal tube changer bougie) and have ports to insufflate oxygen through during the tube change.

CASE HISTORIES

A number of true cases histories are listed below to

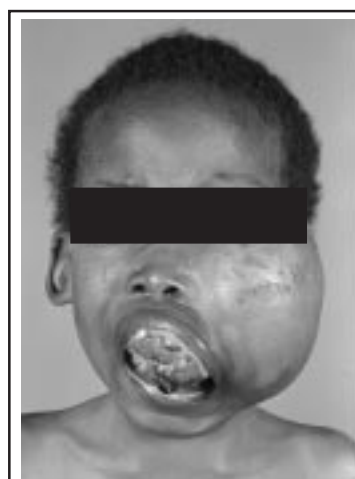illustrate the management of difficult airway problems.

Case History 1

A 55 year old male was scheduled for resection of his parathyroid glands. He was known to be an impossible intubation as he had an immobile neck following spinal surgery and had previously had a failed attempt at a fiberoptic intubation. Tracheostomy was contraindicated because of the site of the surgery and an awake intubation was planned. He received atropine 500mcg premedication and then topical local anaesthesia to the mucosa of his upper airway. Midazolam 3mg was given for sedation, and 4 litres/minute of oxygen was administered throughout the procedure via a catheter in his left nostril. It was not possible to see the larynx with the fiberoptic bronchoscope. A retrograde intubation was carried out under local anaesthesia after placing a central venous line wire through the cricothyroid membrane. The wire came out through his right nostril and a size 7 nasal endotracheal tube was inserted over this into the trachea and the wire withdrawn. Anaesthesia was then induced, surgery performed and he was extubated wide awake at the end of the operation.

Case History 2

A child with a large nasopharyngeal tumour filling his mouth and nose was scheduled for surgical debulking (figure 7). There was clearly no possibility of a conventional oral endotracheal intubation and the patient received a tracheostomy under ketamine anaesthesia to secure the airway. He was given oxygen throughout the tracheostomy through his nose using a small face mask. Anaesthesia was continued via the tracheostomy and surgery performed.



Case History 3

A three year old girl was admitted to hospital with increasingly severe upper airway obstruction and a presumed diagnosis of epiglottitis. She was taken straight to the operating theatre and anaesthesia was induced using oxygen and halothane. The anaesthetist maintained a degree of continuous airway pressure via the T-piece and after a prolonged induction he laryngoscoped the child to reveal a cherry red epiglottitis. The cords were difficult to see until pressure on the chest revealed a bubble at the entrance to the larynx. An appropriate size of endotracheal tube was then inserted. The child was treated with antibiotics and was extubated in theatre 24 hours later when a leak had developed around the tube.

Case History 4

A 28 year old female who was known to be a very difficult intubation was scheduled for removal of a transplanted kidney. She was also known to be awkward to ventilate via a face mask, was very obese and had limited neck movements. Anaesthesia was induced after a successful fiberoptic awake intubation had been performed. During the operation it became impossible to ventilate the patient and after checking for problems with the circuit, airway and bronchi, it was decided that there was a problem with the endotracheal tube. Suction made no difference and the cuff was deflated and the tube pulled back in case it was against the carina. This did not improve the situation and so it was decided to change the endotracheal tube. The tube was removed but it was impossible to ventilate the patient via a face mask. A variety of techniques were tried, including most of the measures mentioned above. The surgeon carried out an emergency tracheostomy, but the patient suffered a hypoxic cardiac arrest. She later died from the complications of this episode. The cause of the difficulty in ventilation has never been satisfactorily explained. The endotracheal tube should have been changed over a tube changer or bougie. This would have minimised the risk of losing access to the trachea, which in this case proved fatal.

Further reading

In addition to the references in the text, articles written by Cobley and Vaughan and Biebuyck [15,16] are recommended. The technique of awake fiberoptic intubation has been well described by Telford and Liban [17].

Practical procedure

An emergency endotracheal tube introducer may be made using a reasonably stiff wire (such as from a wire coathanger) which is inserted inside a nasogastric tube [18]. The tip of the wire should be blunted or bent over before being placed inside the tube. The tube provides a non-traumatic covering for the introducer. The holes at the end could also be used to insufflate oxygen through if the device had to be used as a tube changer. It is easily disassembled for cleaning which should be done thoroughly.

Update in Anaesthesia No 7 described how to make a proper introducer for endotracheal tubes. Portex have recently introduced a range of inexpensive flexible bougies for intubation which have a hole down the centre. Although intended for single use, they could prove very useful to colleagues overseas.

References

1. Cormack RS, Lehane J. Difficult intubation in obstetrics. *Anaesthesia* 1984;39:1105-11
2. Samsoon GLT, Young JRB. Difficult tracheal intubation: a retrospective study. *Anaesthesia* 1987;42:487-90
3. Patil VU, Stehling LC, Zaunders HL. *Fiberoptic Endoscopy in Anesthesia*. Chicago: Year Book Medical Publishers, 1983
4. Frerk CM. Predicting difficult intubation. *Anaesthesia* 1991;46:1005-8
5. Savva D. Prediction of difficult tracheal intubation. *British Journal of Anaesthesia* 1994;73:149-53
6. Calder I, Calder J, Crockard HA. Difficult direct laryngoscopy in patients with cervical spine disease. *Anaesthesia* 1995;50:756-63
7. Wilson ME, Spiegelhalter D, Robertson JA, Lesser P. Predicting difficult intubation. *British Journal of Anaesthesia* 1988;61:211-6
8. Waters DJ. Guided blind endotracheal intubation for patients with deformities of the upper airway. *Anaesthesia* 1963;18:158-62
9. Barriot P, Riou B. Retrograde technique for tracheal intubation in trauma patients. *Critical Care Medicine*. 1988;16:712-3
10. Shanthier TR. Retrograde intubation using the subcricoid region. *British Journal of Anaesthesia*. 1992;68:109-12
11. McCoy EP, Mirakhur RK. The levering laryngoscope. *Anaesthesia* 1993;48:516-9
12. Robelen GT, Shulman MS. Use of the lighted stylet for difficult intubations in adult patients (abstract). *Anesthesiology* 1989;71:A439
13. Frass M, Frenzer R, Zahler J, Lilas W, Leithner C. Ventilation via the esophageal tracheal combitube in a case of

difficult intubation. *Journal of Cardiothoracic Anaesthesia* 1987;1:565-8

14. King TA, Adams AP. Failed tracheal intubation. *British Journal of Anaesthesia* 1990;65:400-414

15. Cobley M, Vaughan RS. Recognition and management of difficult airway problems. *British Journal of Anaesthesia* 1992;68:90-7

16. Biebuyck JF. Management of the difficult adult airway - with special emphasis on awake tracheal intubation. *Anesthesiology* 1991;75:1087-1110

17. Telford RJ, Liban JB. Awake fiberoptic intubation. *British Journal of Hospital Medicine* 1991;46:182-4

18. Bem MJ, Wilson IH. Coathanger wire, as an aid to endotracheal intubation [letter] *Tropical Doctor* 1991;21:122-123
